



IMAGE IN CARDIOLOGY

Superdominant circumflex as culprit of inferior myocardial infarction

Artéria circunflexa superdominante como *culprit* de enfarte agudo do miocárdio inferior

Joana Lima Lopes^{a,*}, Luís Brízida^a, João Bicho Augusto^{a,b}

^a Cardiology Department, Hospital Prof. Doutor Fernando Fonseca, Amadora, Portugal

^b Institute of Cardiovascular Science, University College London, London, UK

Received 5 June 2024; accepted 28 July 2024

Available online 19 September 2024

A 72-year-old male without relevant past medical history presented to the emergency room with severe oppressive chest pain two hours after onset. The electrocardiogram showed ST-segment elevation in the inferior leads with ST-segment depression in I, aVL, V2 and V3 (Figure 1, panel A) and ST elevation in posterior leads suggesting posteroinferior acute ST elevation myocardial infarction (STEMI). An emergent coronary angiography was performed with multiple and unsuccessful attempts at right coronary artery (RCA) catheterization. When left coronary artery catheterization was performed, circumflex artery (Cx) occlusion was identified (Figure 1, panel B) and, after primary coronary intervention (PCI) with a drug-eluted stent (Xience™ 2.75/28 mm post-dilated to 3.25 mm), a superdominant left

Cx was observed (Figure 1, panel C) in a patient with no RCA. The absence of RCA was further confirmed by computed tomography coronary angiography (Figure 1, panels D and E).

Congenital agenesis of RCA is a rare coronary anomaly (under forty published cases)¹ and its diagnosis during STEMI is even rarer. The cause of this is unclear, with some authors suggesting the hypothesis of congenital occlusion of the RCA during the embryonic period.² As a teaching point, we should consider angiography of the non-culprit artery first, as it can reveal major coronary anomalies, such as superdominant vessels, and thus save time by preventing unnecessary attempts at catheterization of a non-dominant or inexistent vessel.

* Corresponding author.

E-mail address: Joana.l.lobes@hff.min-saude.pt (J. Lima Lopes).

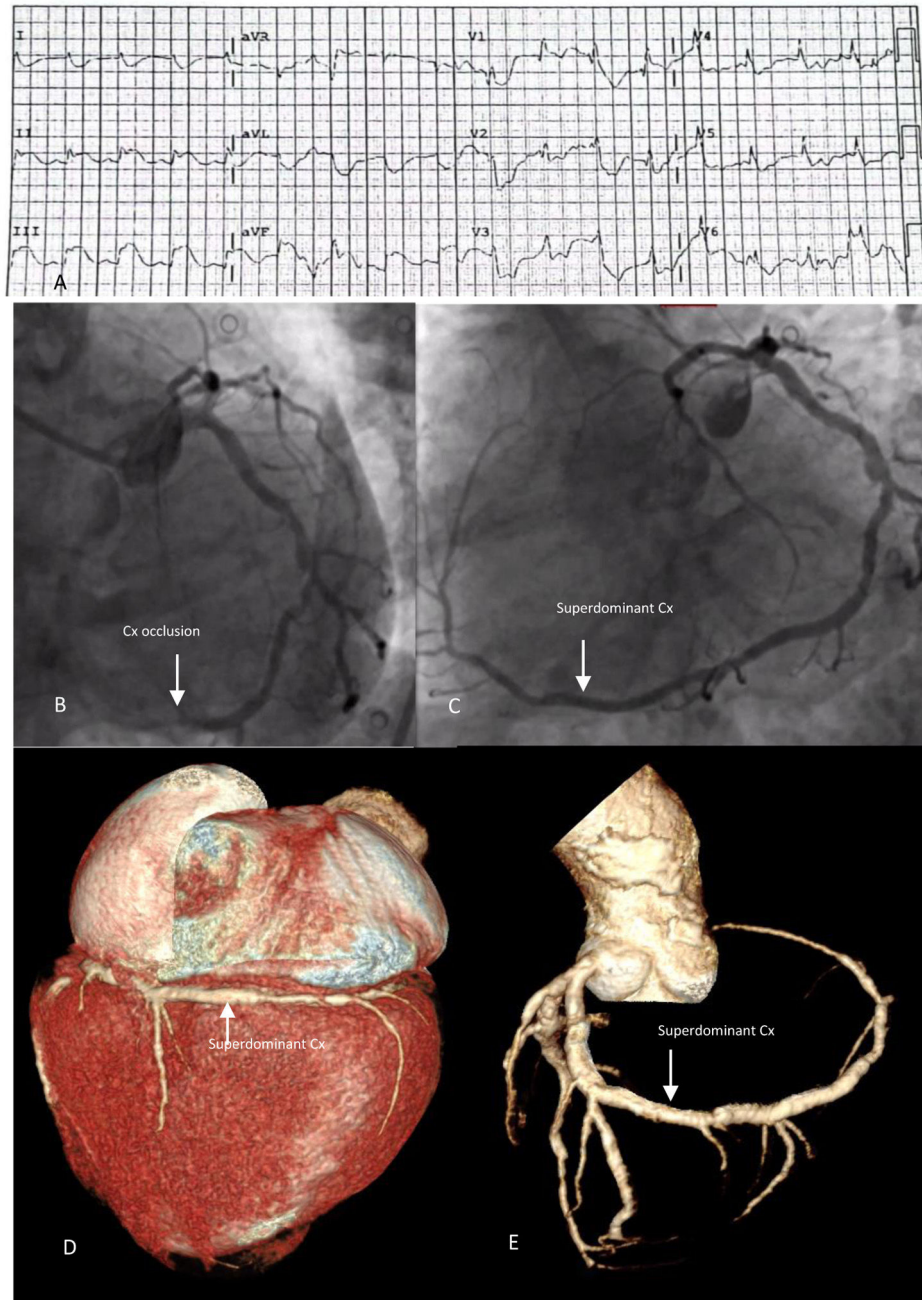


Figure 1 Panel A: ECG with ST-segment elevation in the inferior leads. Panel B: Circunflex (Cx) artery occlusion (arrow) during coronary angiography. Panel C shows a superdominant Cx artery after angioplasty. Panels D and E are CT scan images showing a superdominant Cx artery and absence of right coronary artery (coronary agenesis).

Conflicts of interest

The authors have no conflicts of interest to declare.

References

1. Chen Z, Yan J, Han X, et al. Congenital absence of the right coronary artery with acute myocardial infarction: report of two

cases and review of the literature. *J Int Med Res.* 2020;48, 030006052097150.

2. Yan G-W, Bhetuwal MD, Anup MD, et al. Congenital absence of the right coronary artery. *Medicine.* 2018;97, <http://dx.doi.org/10.1097/md.00000000000010187>.