

CASE REPORT

Giant pericardial cyst mimicking dextrocardia on chest X-ray

Hamad M. Hamad^{a,*}, Ana Galrinho^a, João Abreu^a, Bruno Valente^a, Luis Bakero^b, Rui C. Ferreira^a

^a Serviço de Cardiologia, Hospital de Santa Marta, Lisboa, Portugal

^b Serviço de Cirurgia Cardiorádica, Hospital de Santa Marta, Lisboa, Portugal

Received 2 April 2012; accepted 9 April 2012

KEYWORDS

Pericardial cyst;
Chest X-ray

Abstract Pericardial cysts are rare benign congenital malformations, usually small, asymptomatic and detected incidentally on chest X-ray as a mass located in the right costophrenic angle. Giant pericardial cysts are very uncommon and produce symptoms by compressing adjacent structures. In this report, the authors present a case of a symptomatic giant pericardial cyst incorrectly diagnosed as dextrocardia on chest X-ray.

© 2012 Sociedade Portuguesa de Cardiologia. Published by Elsevier España, S.L. All rights reserved.

PALAVRAS-CHAVE

Quisto pericárdico;
Telerradiografia de tórax

Quisto pericárdico gigante a imitar dextrocardia na telerradiografia de tórax

Resumo Os quistos pericárdicos são malformações congênicas benignas raras. Habitualmente, são de pequena dimensão, assintomáticos e detectados de forma acidental na telerradiografia de tórax, como uma massa localizada no ângulo costofrênico direito. Grandes quistos pericárdicos são ainda mais raros e produzem sintomas por compressão de estruturas adjacentes. Neste artigo, os autores apresentam um caso clínico de um quisto pericárdico gigante e sintomático previamente diagnosticado como uma dextrocardia em telerradiografia de tórax.

© 2012 Sociedade Portuguesa de Cardiologia. Publicado por Elsevier España, S.L. Todos os direitos reservados.

Case report

A 30-year-old man reported dysphagia and weight loss (15 kg) during the previous four months. Palpitations and

chest pain unrelated to physical or emotional stress began two months later. A routine annual visit to the occupational medicine clinic revealed normal physical examination and laboratory tests. The chest X-ray (Figure 1A) suggested a diagnosis of dextrocardia that was not observed on previous annual chest X-rays, and the ECG (Figure 1B) was normal. Outpatient echocardiography was also normal. The patient was referred to the cardiology department for further investigation.

* Corresponding author.

E-mail address: hamadmahmoud77@hotmail.com (H.M. Hamad).

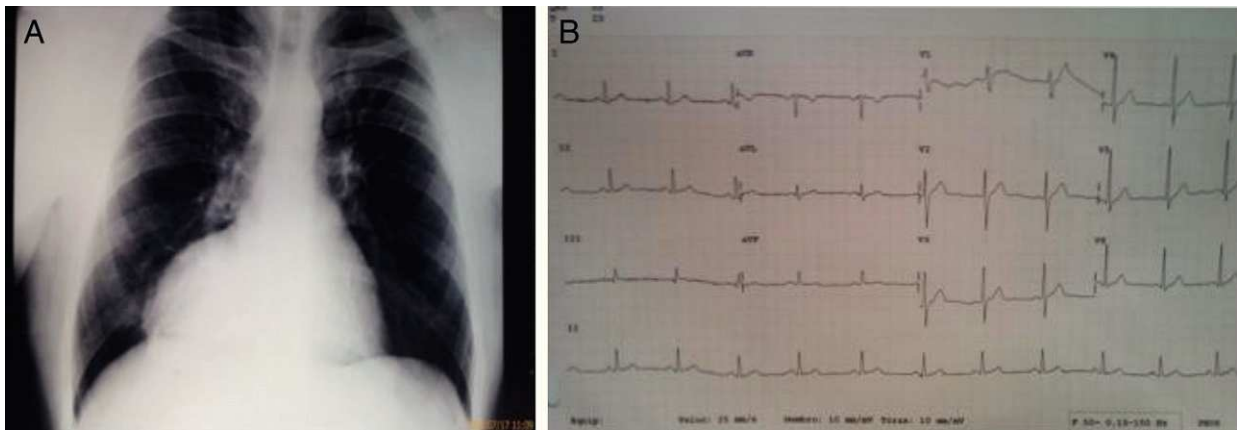


Figure 1 (A) Chest X-ray showing pericardial cyst projecting into the right costophrenic angle mimicking dextrocardia; (B) ECG without abnormalities suggesting dextrocardia.

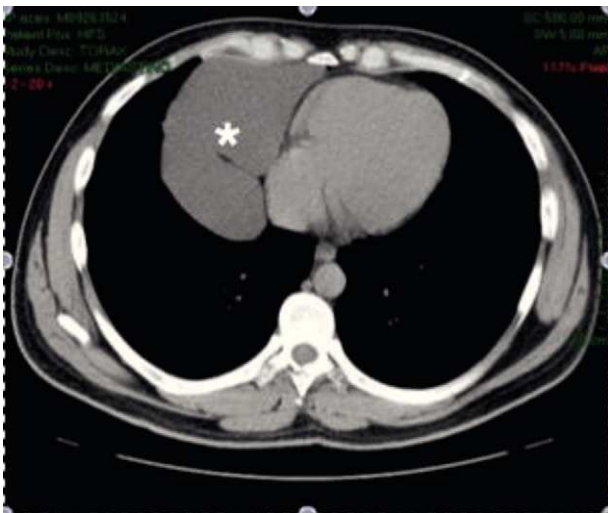


Figure 2 Large mass (*) in the right costophrenic angle on CT scan.

Computed tomography (CT) scan (Figure 2) showed a large well-defined mass 11.2 cm × 7.4 cm in diameter projecting into the right costophrenic angle, suggesting a diagnosis of pericardial cyst or bronchogenic cyst.

Echocardiography (Figure 3) was repeated and revealed an echo-free structure containing a septum, pushing on the right atrium and visualized only from subcostal view, which showed a large pericardial cyst, and no other abnormal findings.

Magnetic resonance imaging (MRI) (Figure 4) identified a non-enhanced, well-defined bilobed mass in the right costophrenic angle containing clear fluid with a volume of 70.4 ml, compatible with a giant pericardial cyst.

The patient underwent surgical excision of the mass (Figure 5) without complications. Histological examination confirmed the diagnosis of pericardial cyst. After three months of follow-up, he was symptom-free and the chest X-ray (Figure 6) showed no signs of dextrocardia.

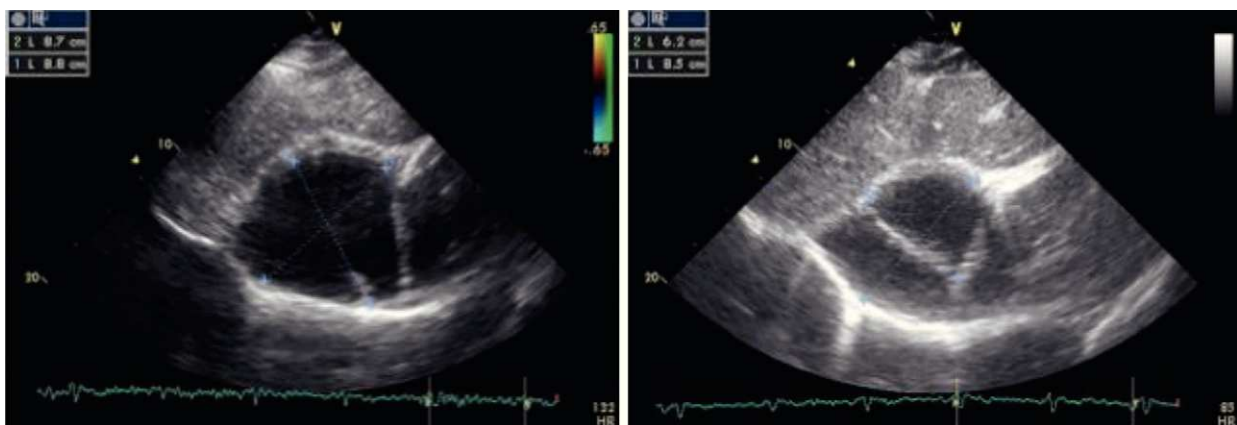


Figure 3 Echocardiography, subcostal view, with a 87 mm × 88 mm mass containing a septum, suggesting a diagnosis of large pericardial cyst.

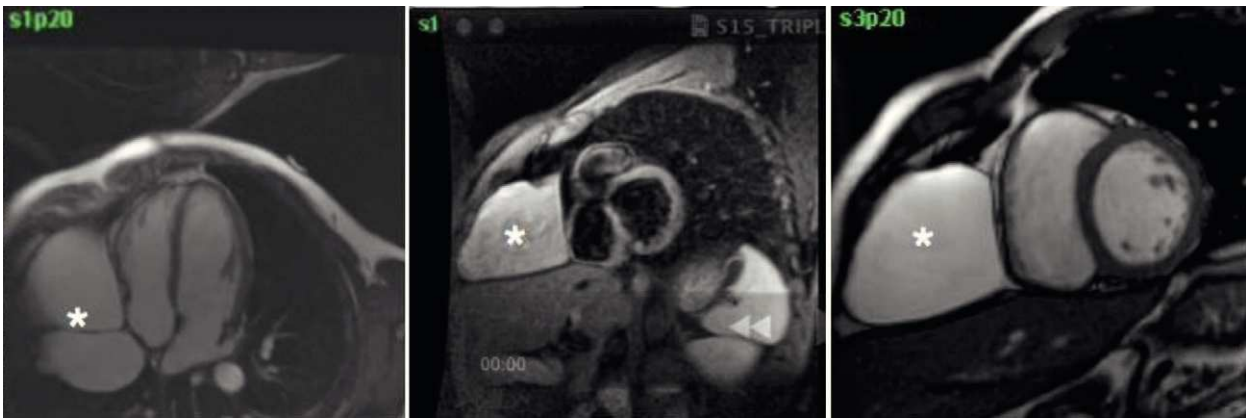

Figure 4 Magnetic resonance image showing a bilobed mass (*) containing clear fluid in the right costophrenic angle.

Discussion

Pericardial cysts are rare benign structures, most frequently located in the right costophrenic angle, but may also appear in the left costophrenic angle, hilum and superior

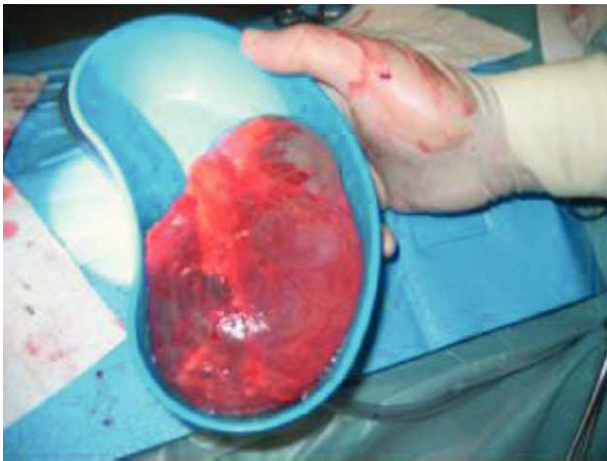

Figure 5 Pericardial cyst after excision.

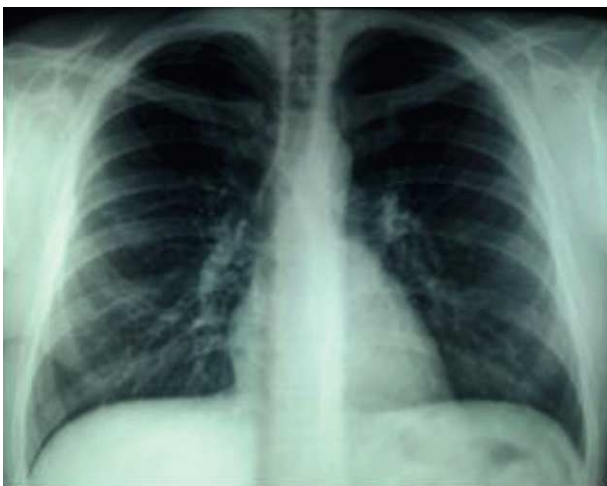


Figure 6 Chest X-ray three months after surgery.

mediastinum. They may be unilocular or multilocular with diameters ranging between 1 and 5 cm.¹ In our case the pericardial cyst was very large, almost 9 cm in diameter, which makes it even more rare. The incidence of pericardial cysts is 1:100 000 and they represent 6–7% of total mediastinal masses.² They must be differentiated from cardiac chamber enlargement, diaphragmatic hernia, malignant tumors and bronchogenic cysts.

Pericardial cysts are usually asymptomatic and discovered incidentally on chest X-ray or echocardiography,³ while MRI and CT can differentiate between pericardial cyst and other solid mediastinal masses.^{1,2} The former appears as a thin-walled, well-defined mass filled with clear fluid without intravenous contrast enhancement.

Giant pericardial cysts may cause chest pain, dyspnea and cough secondary to airway compression. They may produce symptoms mimicking tricuspid stenosis, pulmonary stenosis or constrictive pericarditis.⁴ Atrial fibrillation,⁵ cardiac tamponade⁶ and even sudden death after a stress test⁷ have been reported. To the best of our knowledge, symptoms of dysphagia and significant weight loss, as in our case, have not previously been reported.

Treatment for symptomatic patients with large cysts includes surgical excision or percutaneous aspiration and alcohol sclerosing injection to prevent recurrence. Asymptomatic patients should be followed to monitor for possible future symptoms.

Ethical disclosures

Protection of human and animal subjects. The authors declare that the procedures followed were in accordance with the regulations of the relevant clinical research ethics committee and with those of the Code of Ethics of the World Medical Association (Declaration of Helsinki).

Confidentiality of data. The authors declare that they have followed the protocols of their work center on the publication of patient data and that all the patients included in the study received sufficient information and gave their written informed consent to participate in the study.

Right to privacy and informed consent. The authors have obtained the written informed consent of the patients or subjects mentioned in the article. The corresponding author is in possession of this document.

Conflicts of interest

The authors have no conflicts of interest to declare.

References

1. Maisch B, Seferovic PM, Ristic AD, et al. Guidelines on the diagnosis and management of pericardial diseases executive summary. The Task Force on the Diagnosis and Management of Pericardial Diseases of the European Society of Cardiology. *Eur Heart J.* 2004;25(7):587–610.
2. Caramori JE, Miozzo L, Formigheri M, et al. Dispneia por compressão de estruturas mediastinais por cisto pericárdico. *Arq Bras Cardiol.* 2005;84(6):486–7.
3. Lau CL, Davis RD. The mediastinum. *Sabiston's textbook of surgery*, vol. 21, 17th ed. Philadelphia: Elsevier; 2004. p. 1738–9, 1758 [chapter 56].
4. Klatte EC, Yune HY. Diagnosis and treatment of pericardial cyst. *Radiology.* 1972;104:541–4.
5. Vlay SC, Hartman AR. Mechanical treatment of atrial fibrillation: removal of pericardial cyst by thoracoscopy. *Am Heart J.* 1995;129:616–8.
6. Shiraishi I, Yamagishi M, Kawakita A, et al. Acute cardiac tamponade caused by massive hemorrhage from pericardial cyst. *Circulation.* 2000;101:E196–7.
7. Fredman CS, Parsons SR, Aquino TI, et al. Sudden death after a stress test in a patient with a large pericardial cyst. *Am Heart J.* 1994;127(4 pt 1):946–50.